Sternal wound infection

Dr Adeeb Tanous

- Sternal wound infections following cardiac surgery :

1- Increase morbidity and mortality.

2-Prolong hospital length of stay.

3-Increase medical costs.

- Risk Factors : older age ,diabetes,females,obesity,long complex operations and emergent surgery.
- Coagulase-negative staphylococcus and S.aureus are the most common pathogens encountered.
- The American Association For Thoracic Surgery (AATS) published guidelines for the prevention of wound infection during the preoperative , intraoperative and postoperative periods as well as techniques and methods to treat sternal wound infections should they occur.

PREOPERATIVE PREVENTION

- Decreasing bacterial colonization:

*All cardiac surgery patients should have nasal swabs and polymerase chain reaction (PCR) testing, if available, prior to Surgery.

*Routine mupirocin administration is recommended for all cardiac surgery procedures.

*Presurgical bathing with chlorhexidine may be helpful in reducing skin bacterial counts .

Reducing risk factors responsible for sternal wound infection

- Nutritional status :

Patients with poor nutritional status have a higher incidence of sternal wound infections, especially elderly patients with a serum albumen < 2.5 g/ml, and those with greater than a 10% total body weight loss within 6 months of surgery .

Preoperative nutritional support via an enteral route shoul be instituted in those patients in whom surgery can be safely delayed for 7–10 days.

- Remote, extrathoracic infections:

All distant, extrathoracic infections should be treated prior to cardiac surgical procedures .

Infections involving the urinary tract, lungs, abdominal organs, and soft tissues significantly increase the incidence of wound infections .

- Optimizing glycemic control :

Optimizing glycemic control is preferable in patients with elevated HbAIc levels > 7.5 and serum glucose levels > 200 mg/dl prior to any cardiac surgery procedure .

- Smoking cessation and aggressive pulmonary toilet :

should be performed in patients who are active smokers and those with chronic obstructive pulmonary disease COPD . Whenever possible, patients should stop smoking for at least 30 days prior to surgery . Aggressive preoperative pulmonary physiotherapy should be performed to loosen secretions and minimize mucus plugging to prevent increased coughing which contributes to sternal instability and ultimately sternal dehiscence and mediastinitis.

- Preoperative antibiotics :

* A cephalosporin, either cefazolin or cefuroxime, should be given within 60 min prior to the skin incision and be continued for no longer than 48 h .
* Vancomycin is reserved for patients with a history of type I allergic reactions to a beta-lactam agent .
* Vancomycin is not recommended as the sole prophylactic antibiotic for cardiac surgery procedures .
* An aminoglycoside should be added for one preoperative and at most one additional dose for gram negative coverage when vancomycin is the primary prophylactic antibiotic.
* Vancomycin should be given not only for patients who are allergic to beta-lactam agents but also for patients hospitalized for > 3 days, patients transferred from another in-patient facility , or institutions where there is a high prevalence of MRSA and for those procedures involving a prosthetic valve or a vascular graft.
*Antibiotic should be re-dosed for procrdures lasting more than 4 h .

Intraoperative prevention

- Antibiotic :

Timing is important when re-dosing antibiotics during cardiac surgical procedures.

Intraoperative re-dosing of Cefazolin has been shown to significantly reduce infections when cardiac surgical procedures last longer than 4 h, and cardiopulmonary bypass times exceed 120 min .

- Glycemic control:

Serum glucose < 180 mg/dl .

Continuous intravenous insulin infusions should be instituted to maintain serum glucose levels < 180 mg/dl.

- Topical antibiotic:

Topical antibiotics should be applied to the cut edges of the sternum upon opening and prior to closing the Sternum.

Topical Vancomycin reduced the incidence of sternal wound linfections from 3.6 to 0.5% .

Topical Vancomycin is inexpensive, easy to prepare and handle, and has no local or systemic side-effects. It provides both bacteriocidal and bacteriostatic protection against gram-positive bacteria and clostridia organisms.

- Avoid bone wax :

Bone wax should not be applied to the cut edges of the Sternum.

- Intraoperative techniques to maintain sternal stability:

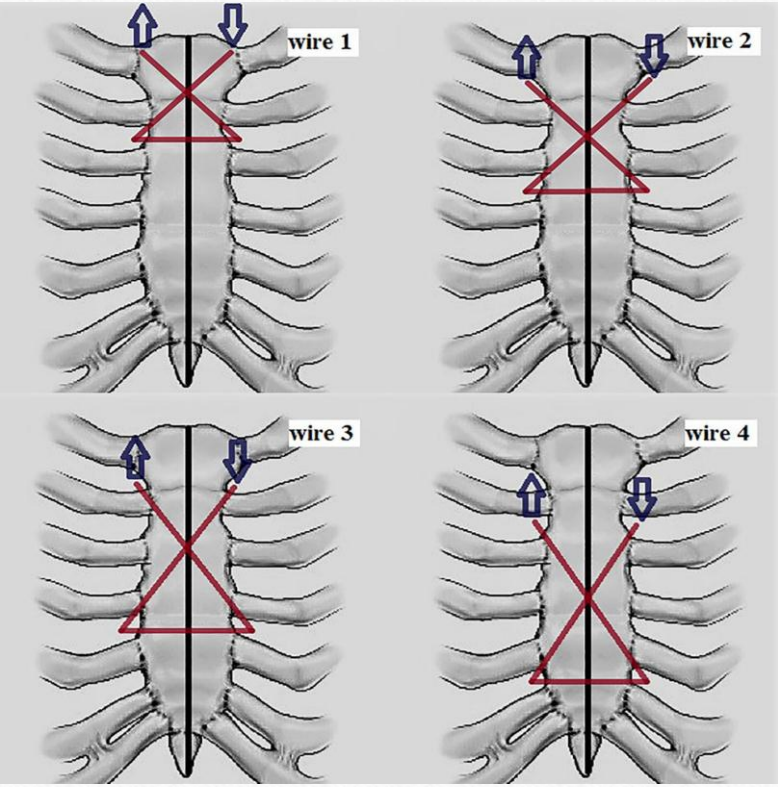

figure of eight technique

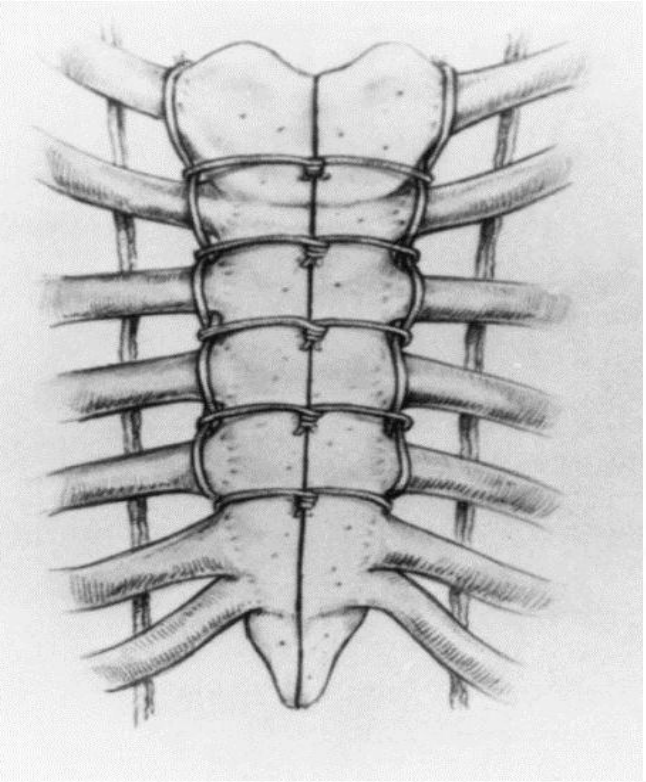

Robicsek weave technique

Rigid sternal fixation

Closing the sternum with a figure of eight technique is preferable to prevent sternal dehiscence and wound infections.

Postoperative prevention

- Chest wall stabilization:

External chest support vests may limit the incidence of sternal dehiscence and infections .

- Antibiotics:

  STS guidelines recommend that prophylactic antibiotics be given for no longer than 48 h following surgery. Vancomycin,when used in combination with other antibiotics, should only be given for one additional postoperative dose.

- Glycemic control:

  Serum glucose should be < 180 mg/dl.

- Drainage and indwelling catheters:

  All chest drainage catheters should be removed as soon as drainage decreases. Indwelling urinary and central venous catheters serve as a potential nidus for infection and should be removed when vital signs stabilize and frequent hemodynamic monitoring is no longer necessary.

Guidelines for management of sternal infections

- Use of dilute povidine-iodine irrigation for treatment of deep sternal wound infections with mediastinitis should be avoided.
- Negative pressure wound therapy (NPWT) should be initiated whenever possible in patients in whom delayed sternal closure is anticipated following deep sternal wound infections.
- When using negative pressure wound therapy, it is necessary to place a barrier dressing between the sponge and the heart and great vessels to prevent tissue erosion resulting in fatal hemorrhage.

In superficial infections, incision and drainage followed by packing and dressing changes may be all that is needed.

Superficial Sternal Wound Infection

For deeper infections associated with sternal necrosis and chest wall instability, other techniques are necessary.

In patients in whom a primary sternal wound closure cannot be performed, sternal wound flap closure with muscle or omentum is now the procedure of choice.

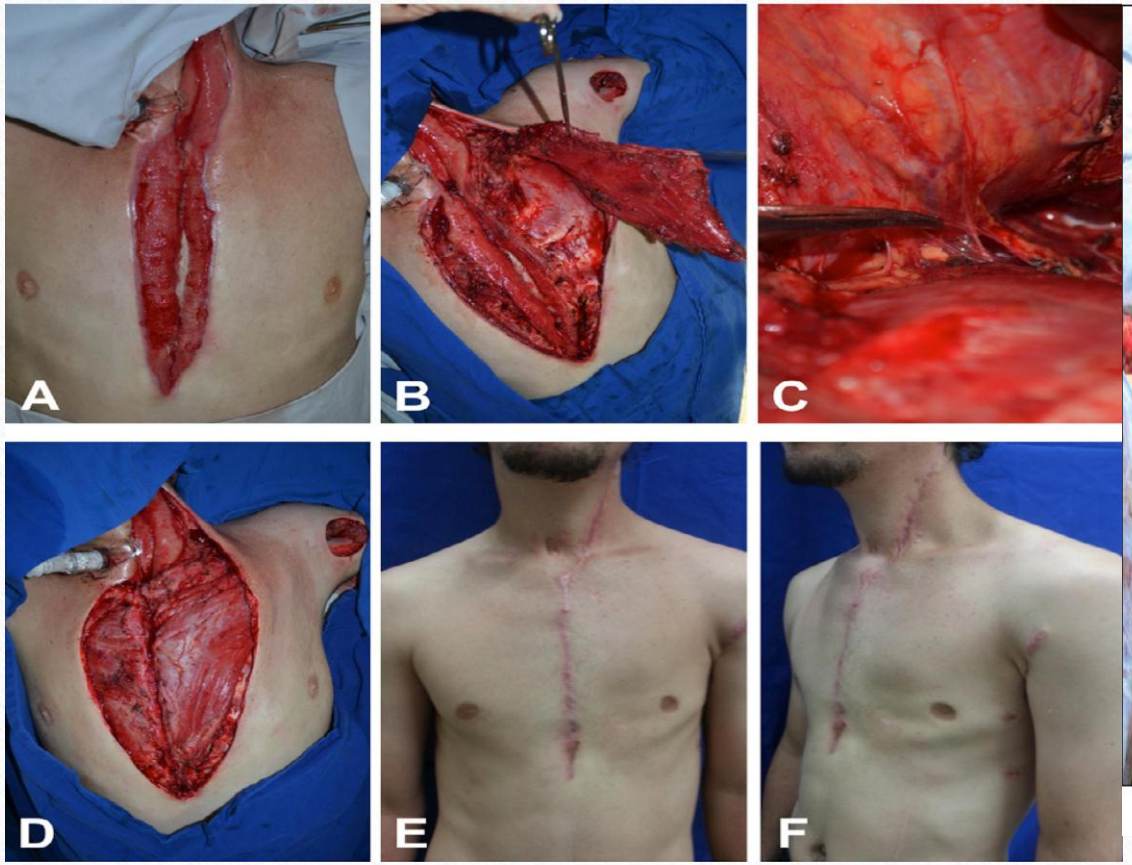

Figure 3: Isolated pectoralis major muscle flap

Figure 4: Mobilised bilateral pectoralis muscles with release of humeral head of the left side

Sternal Wound Closure with Pectoralis Muscle Flaps

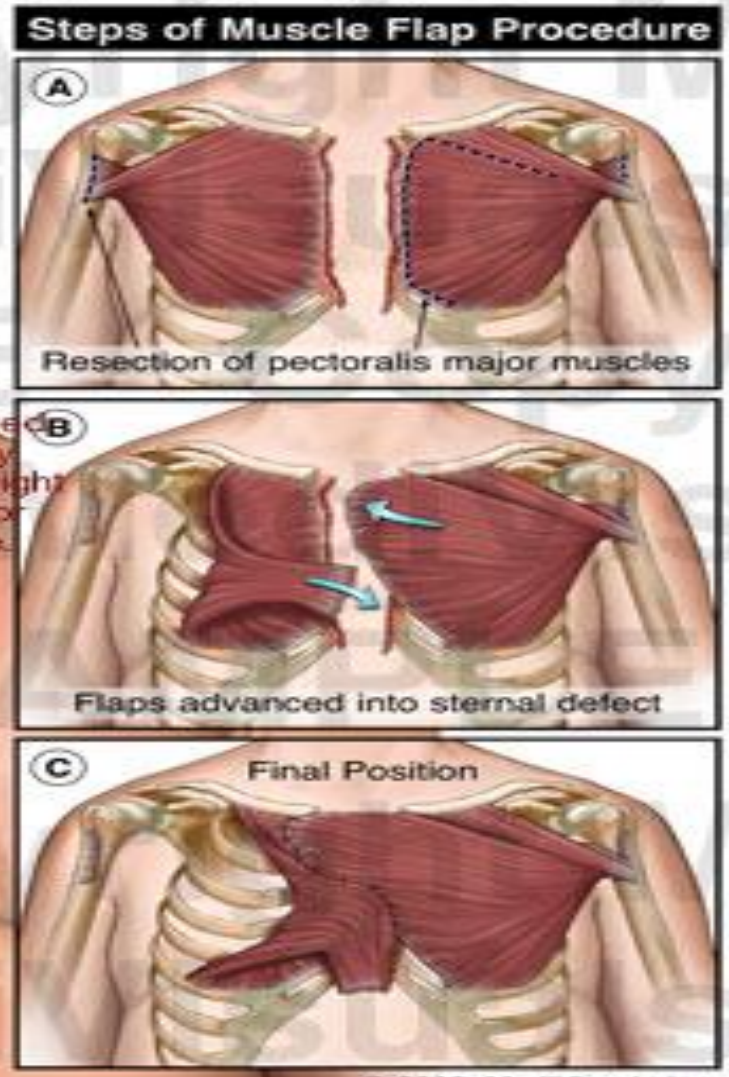

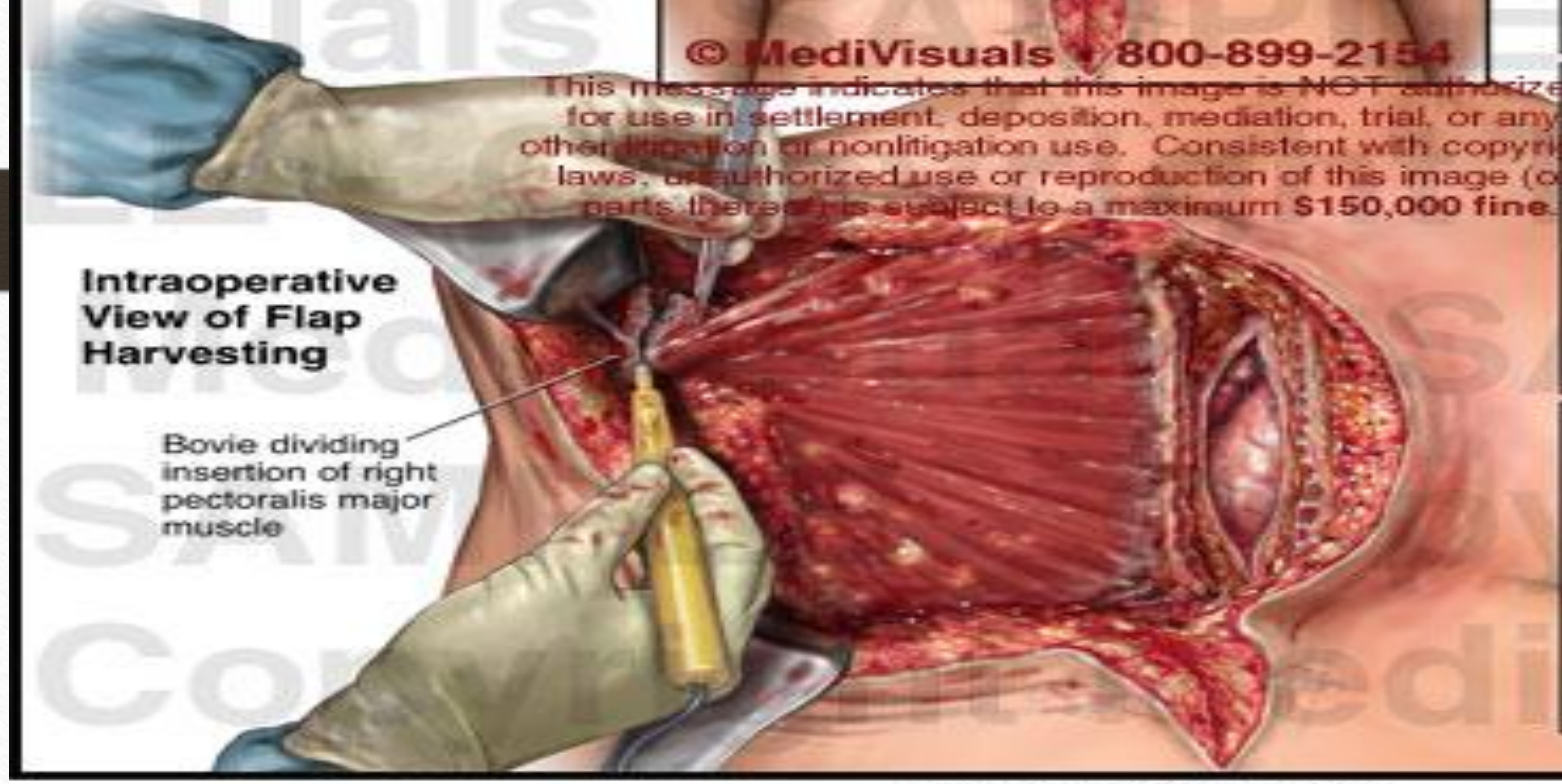

Exhibit# R15695_05XG

Before proceeding with flap closure, the wound must be free of active infection and all necrotic tissue must be debrided. In order to bridge these patients to a permanent flap closure, negative pressure wound therapy should be instituted.

NPWT stabilizes the chest wall and allows for earlier extubation, removes excess fluid and decreases wound edema, accelerates wound healing, and has resulted in earlier wound closure, shorter hospital stays, and decreased mortality . In order to avoid fatal exsanguination from exposed myocardium, great vessels, and bypass conduits.

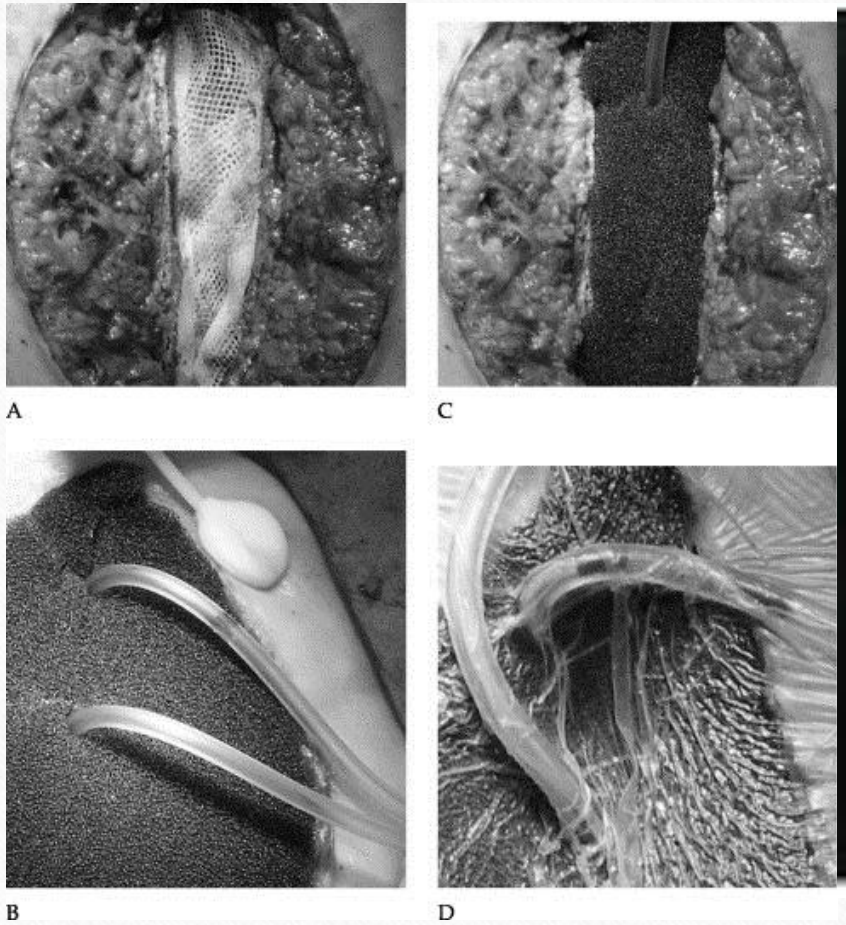

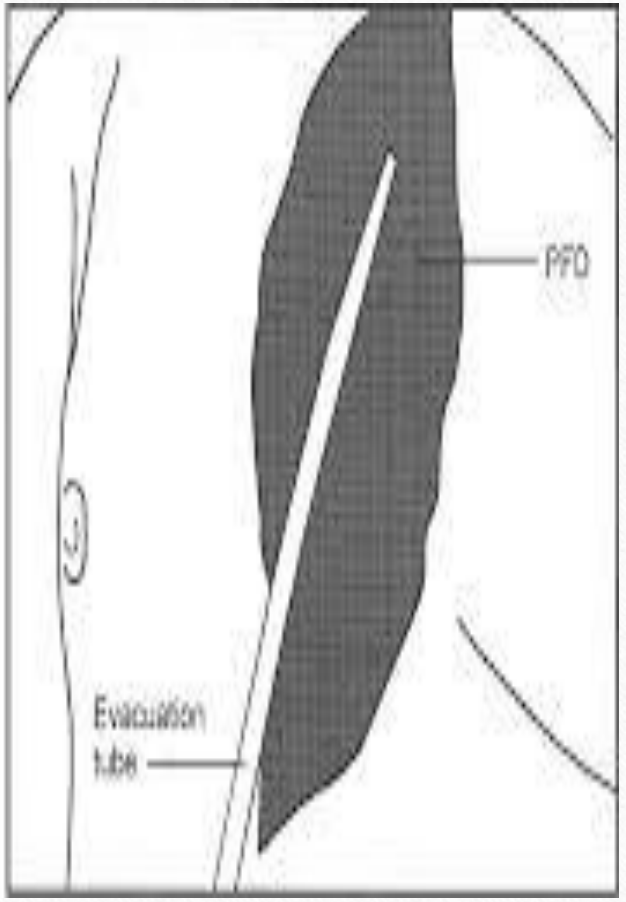

The End