Hemiarch Replacement

Case report

- male
- **58** years

- Past medical : **HTN**

- **Main complaint**: tearing chest pain that radiates to the back between scapulae

- Albassel Aleppo 28/9 – 30/9

Echocardiography

- Ef = **60%**
- **Concentric** hypertrophy
- AR = ¼
- Aortic **root** dilatation

medications

- ASA
- CLOPIDOGREL
- ATORVASTATIN
- CAPTOPRIL
- METOPROLOL

Laboratory

- **Cr**: 1
- **K**: 3.8
- **troponin** : (-)
- **CkMB**: **16**
- **Hgb**: 13, **10**
- **Wbc**: **5,2** , 13
- **Glu**: 113, **221**

Multislice CT scan 3/10

Multislice CT scan

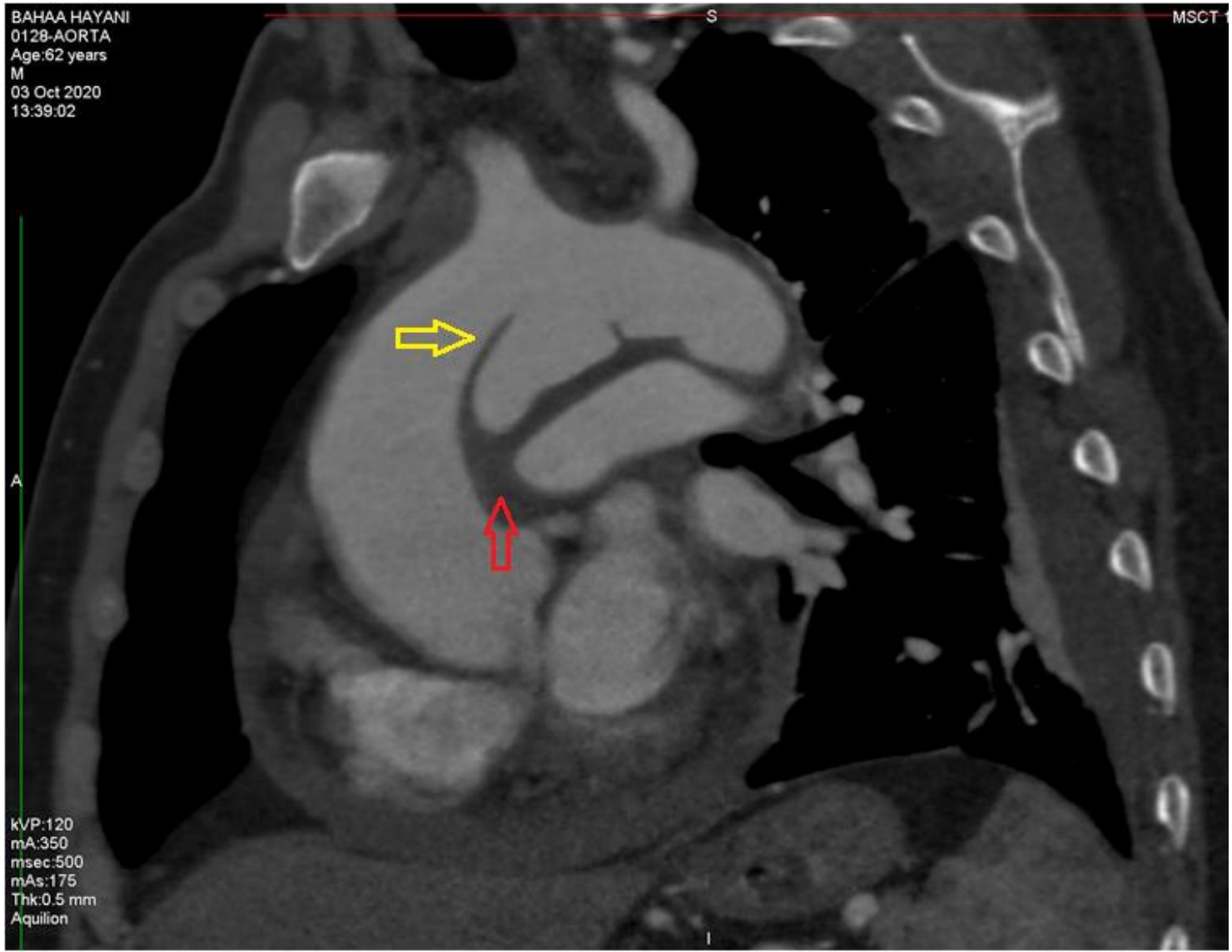

Multislice CT scan

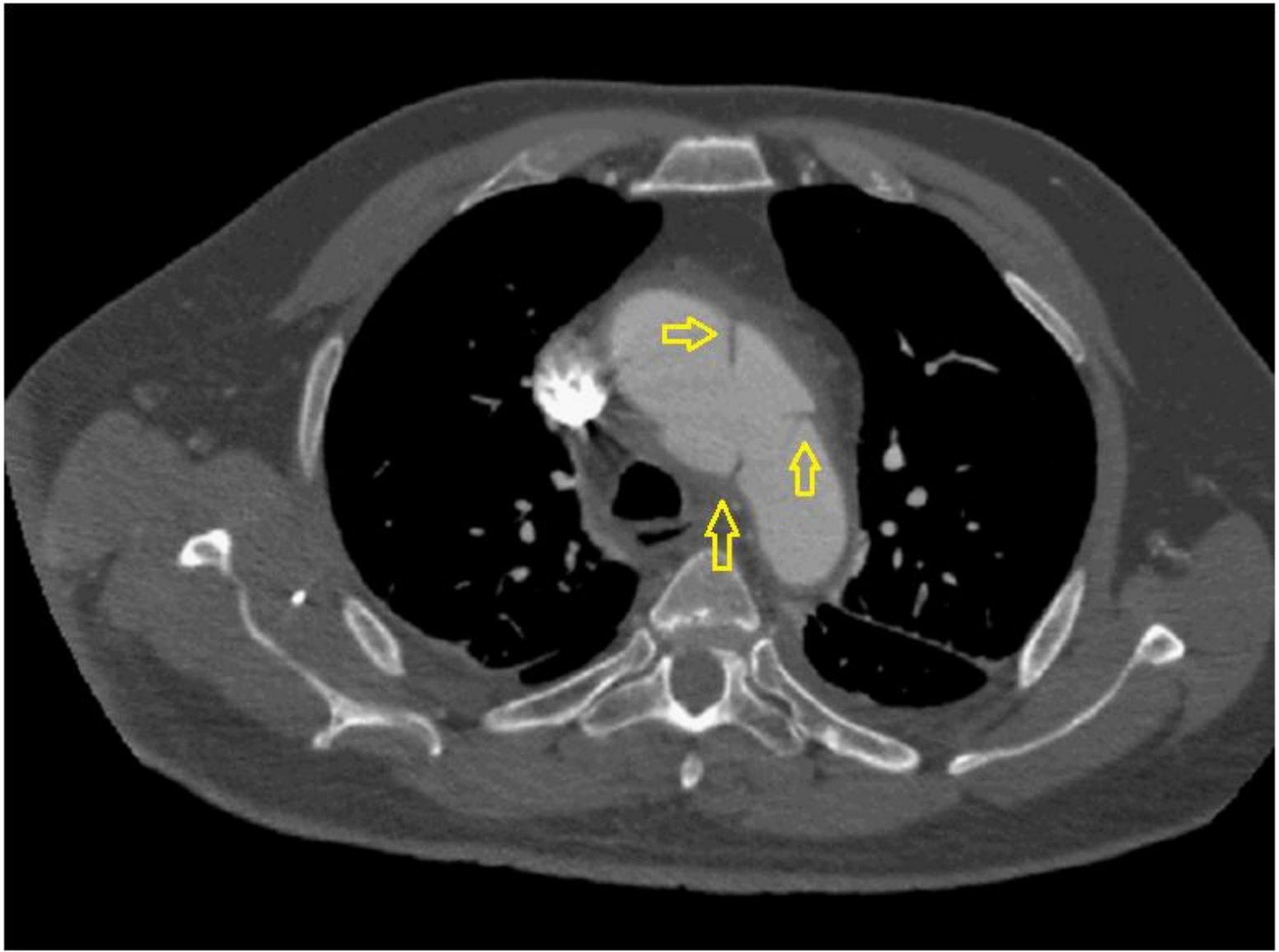

Multislice CT scan

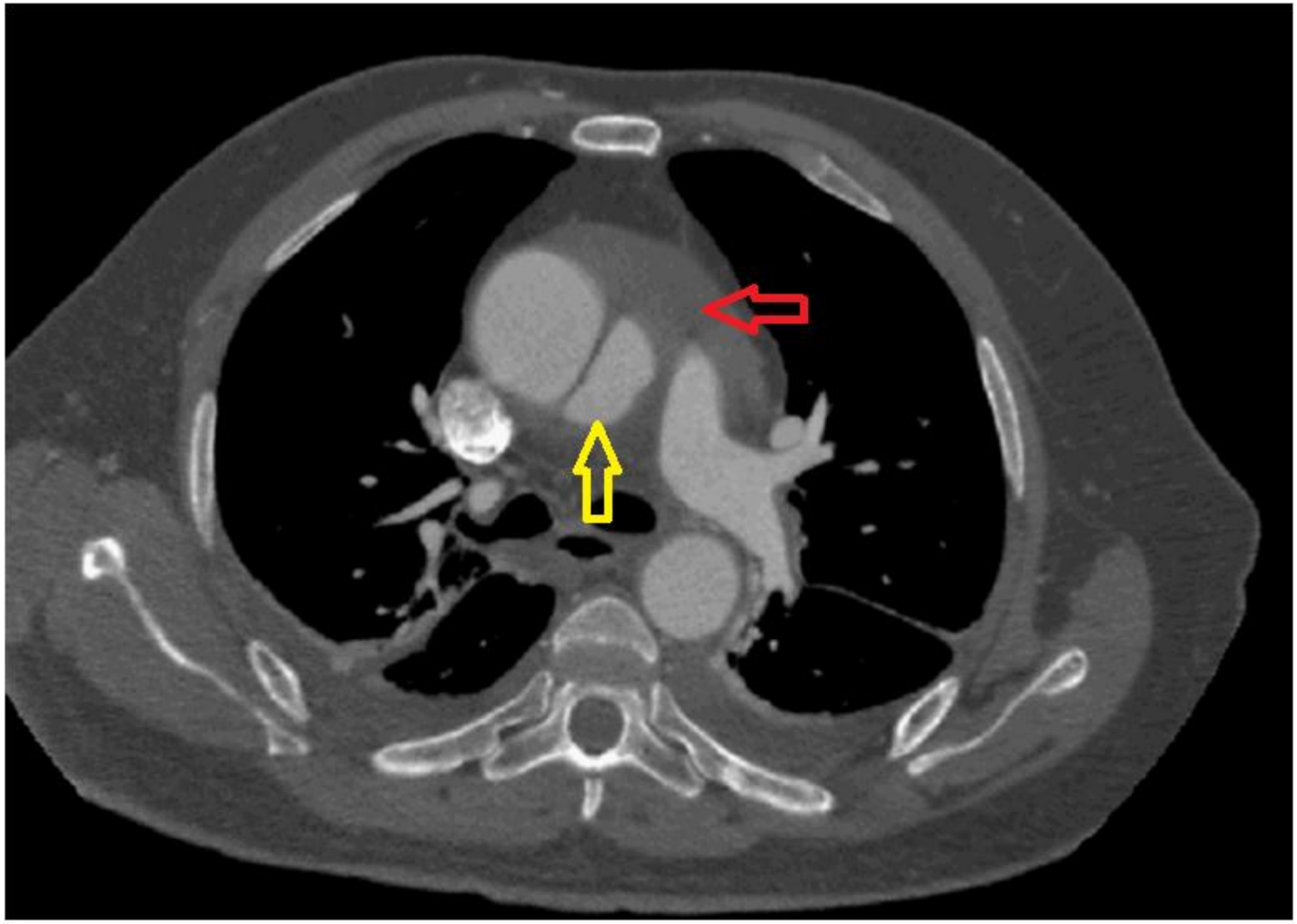

Multislice CT scan

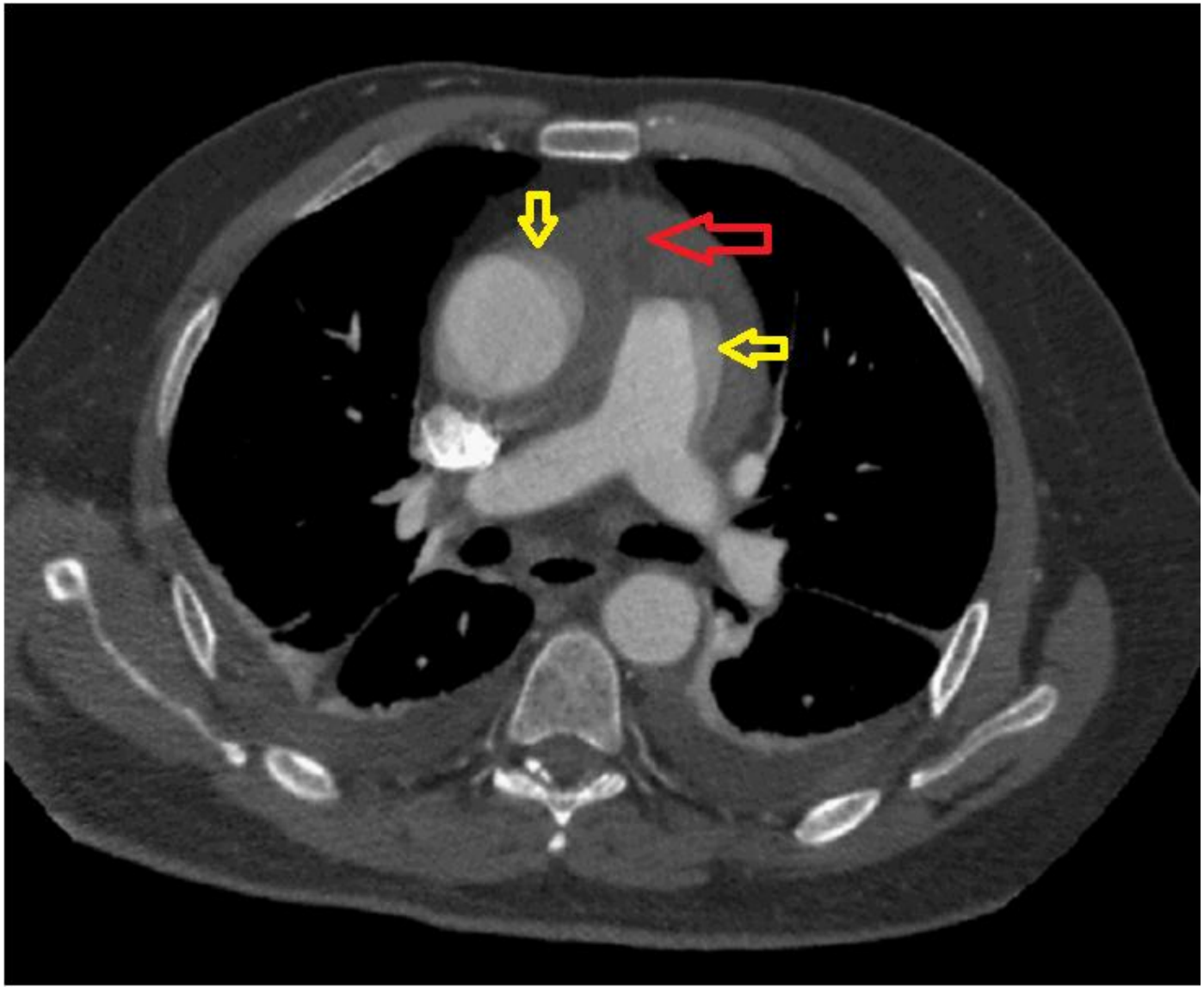

Multislice CT scan

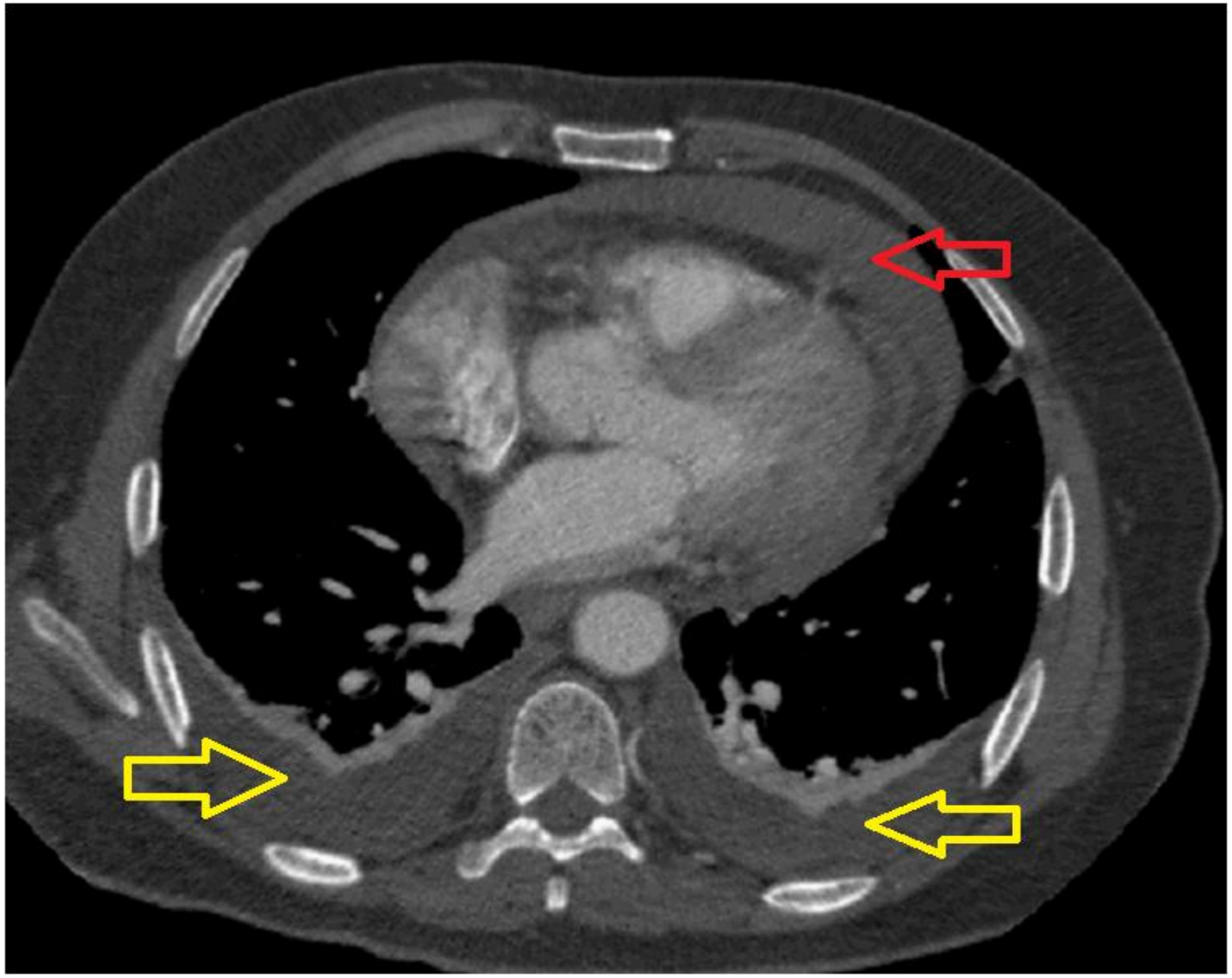

- Albassel heart institute
- **30/9 – 8/10**

- **Surgery:** 5/10

- **Hemiarch replacement**

- **Conduit**: 26

- Right **femoral** artery cannulation
- Right **axillary** artery cannulation: side arm 8
- Right **atrial** cannulation

- **Hemopericardium**
- Lesser curvature **intramural hematoma**

- Distal ascending aorta **clamp**
- **cardioplegia**
- **Deep hypothermia :** 24°
- **Femoral** circulatory arrest: **30 min**
- Removing clamp : **open lumen**
- **Distal** anastomosis near the origin of **brachiocephalic** trunk
- **Proximal** anastomosis: **3-4 cm above STJ**

Uncontrolled bleeding :

- gauze **pack** removed **36 hr** later

Right Axillary Artery Cannulation: Side Arm 8

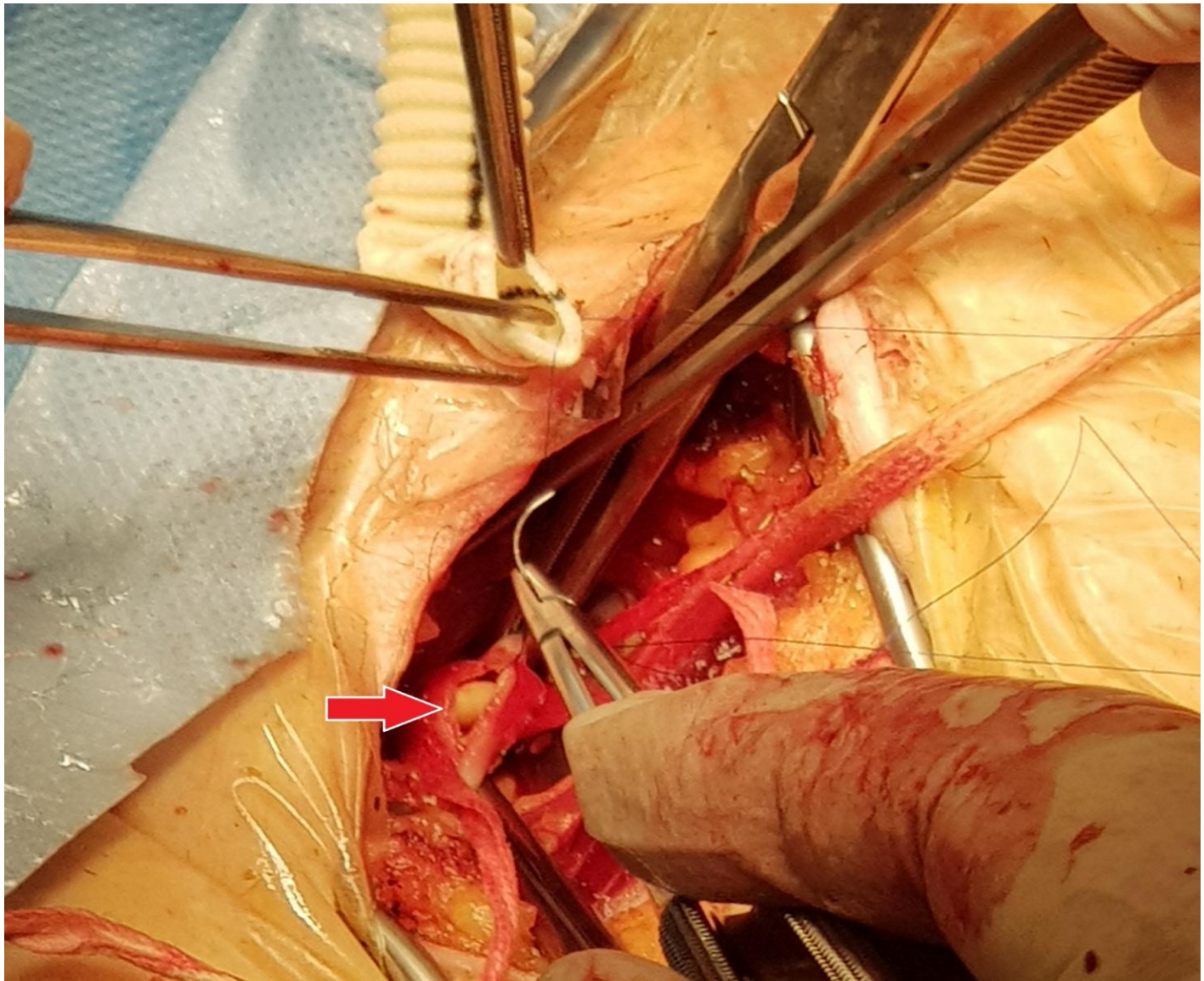

Right Axillary Artery Cannulation: Side Arm 8

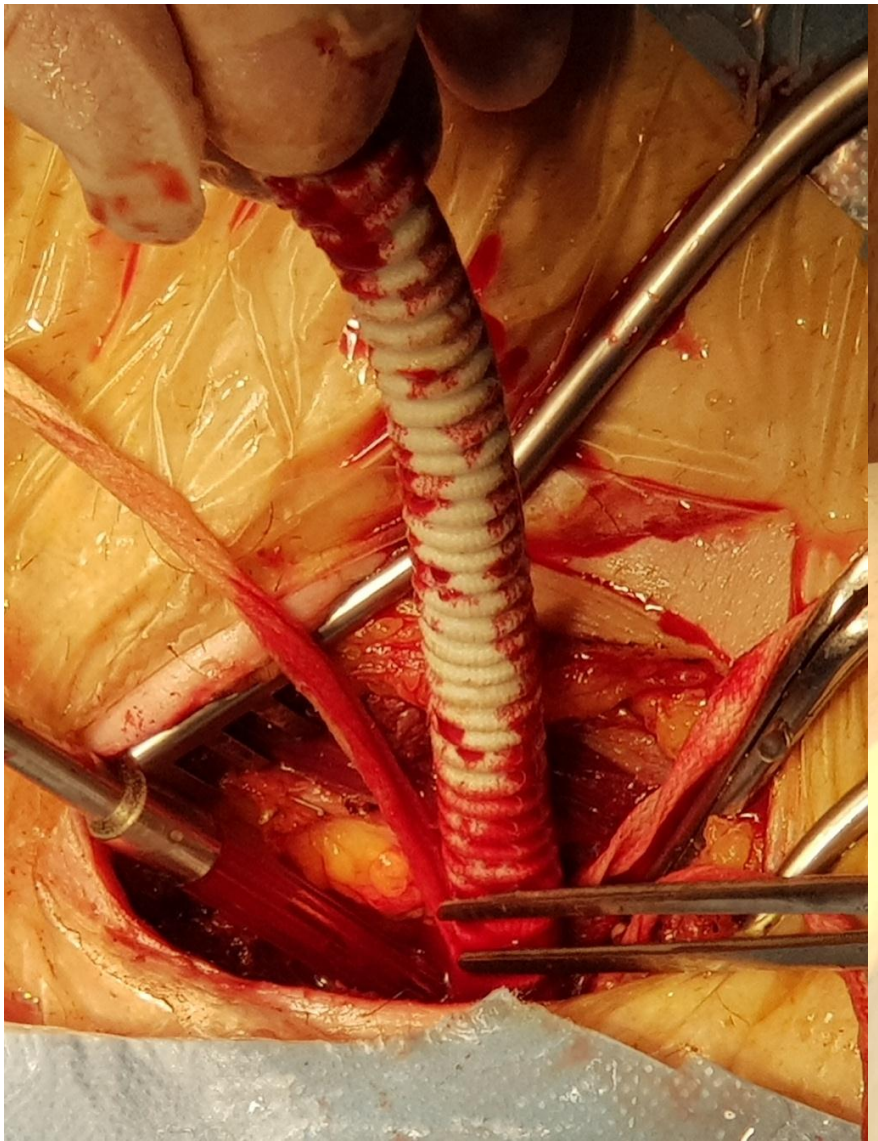

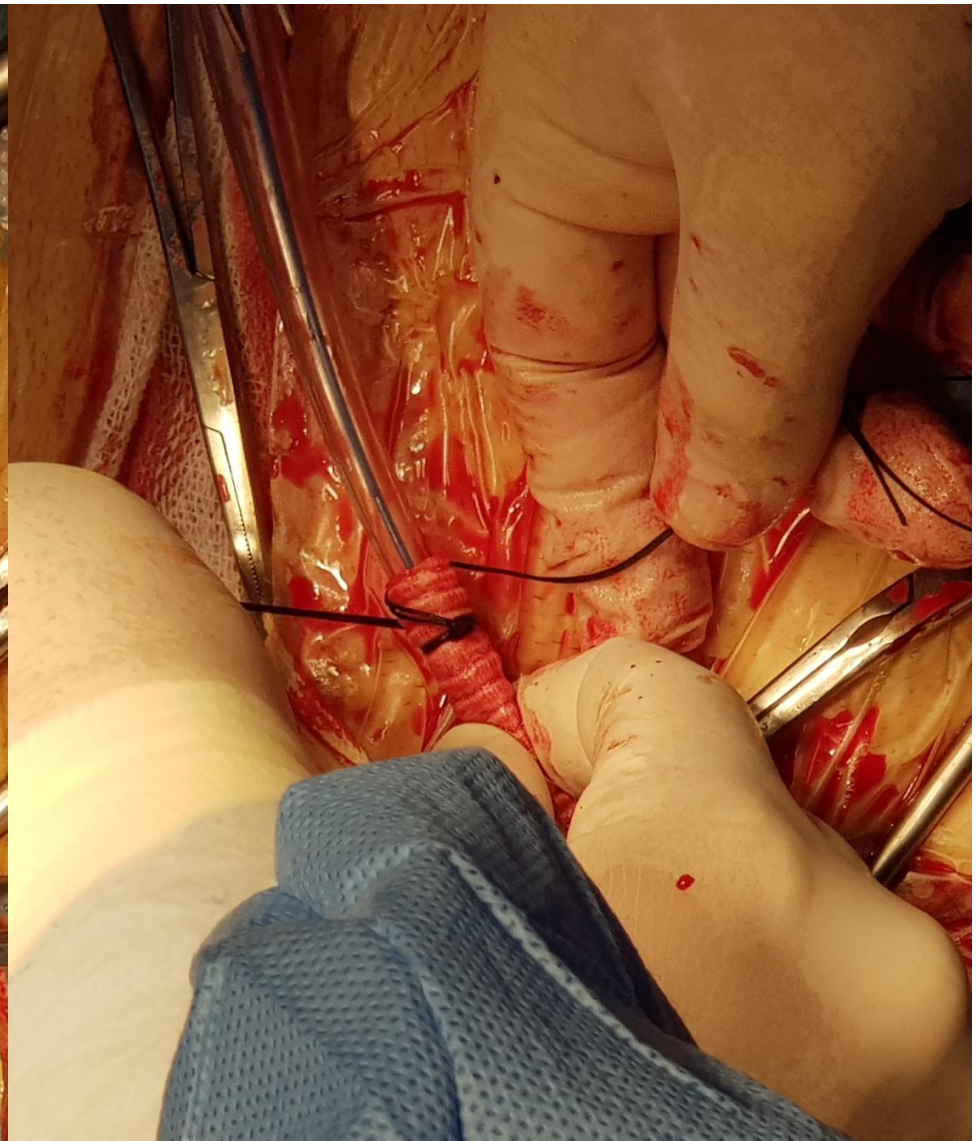

Right Axillary Artery Cannulation: Side Arm 8

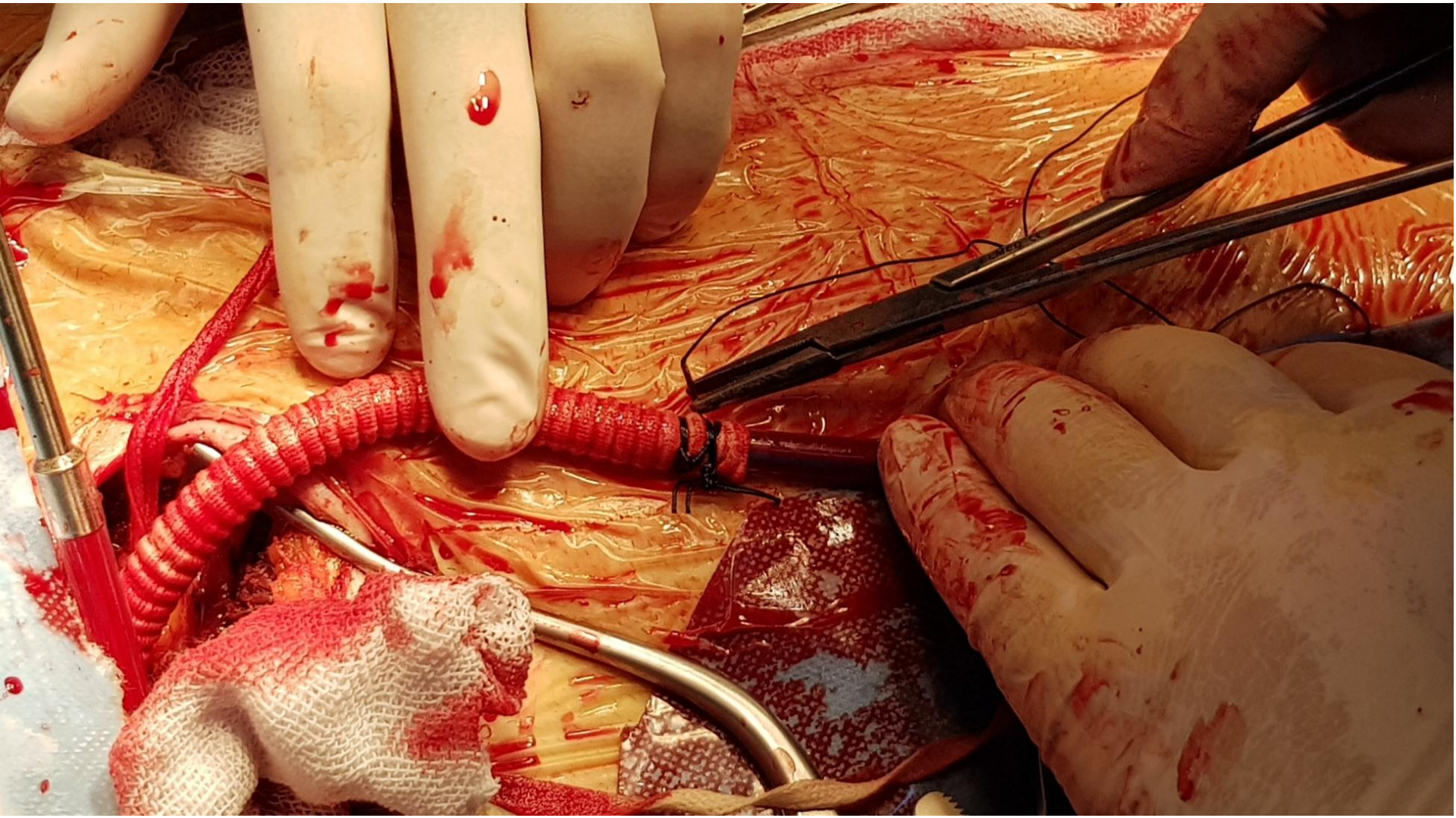

Right Femoral Artery Cannulation

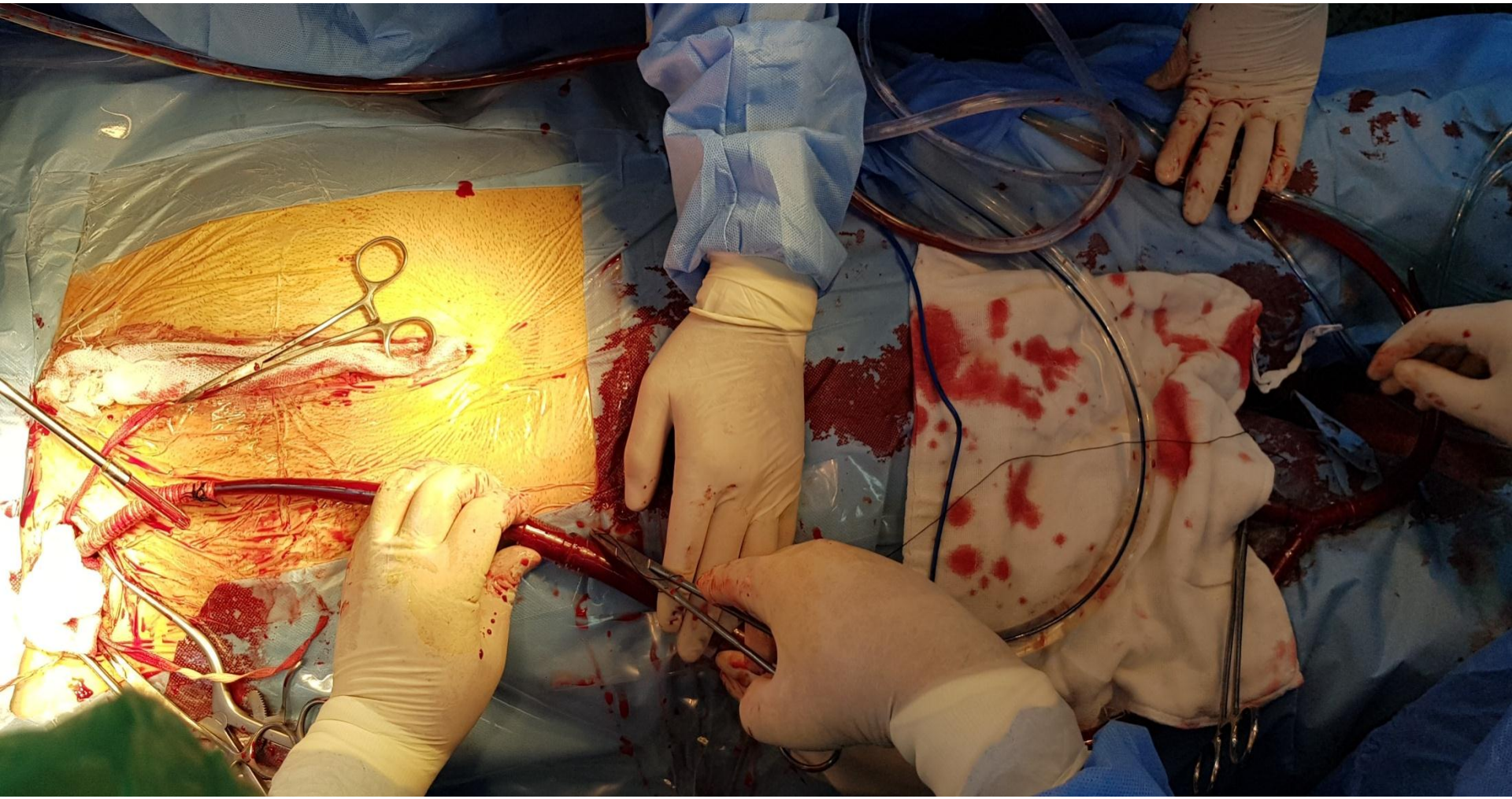

Hemopericardium

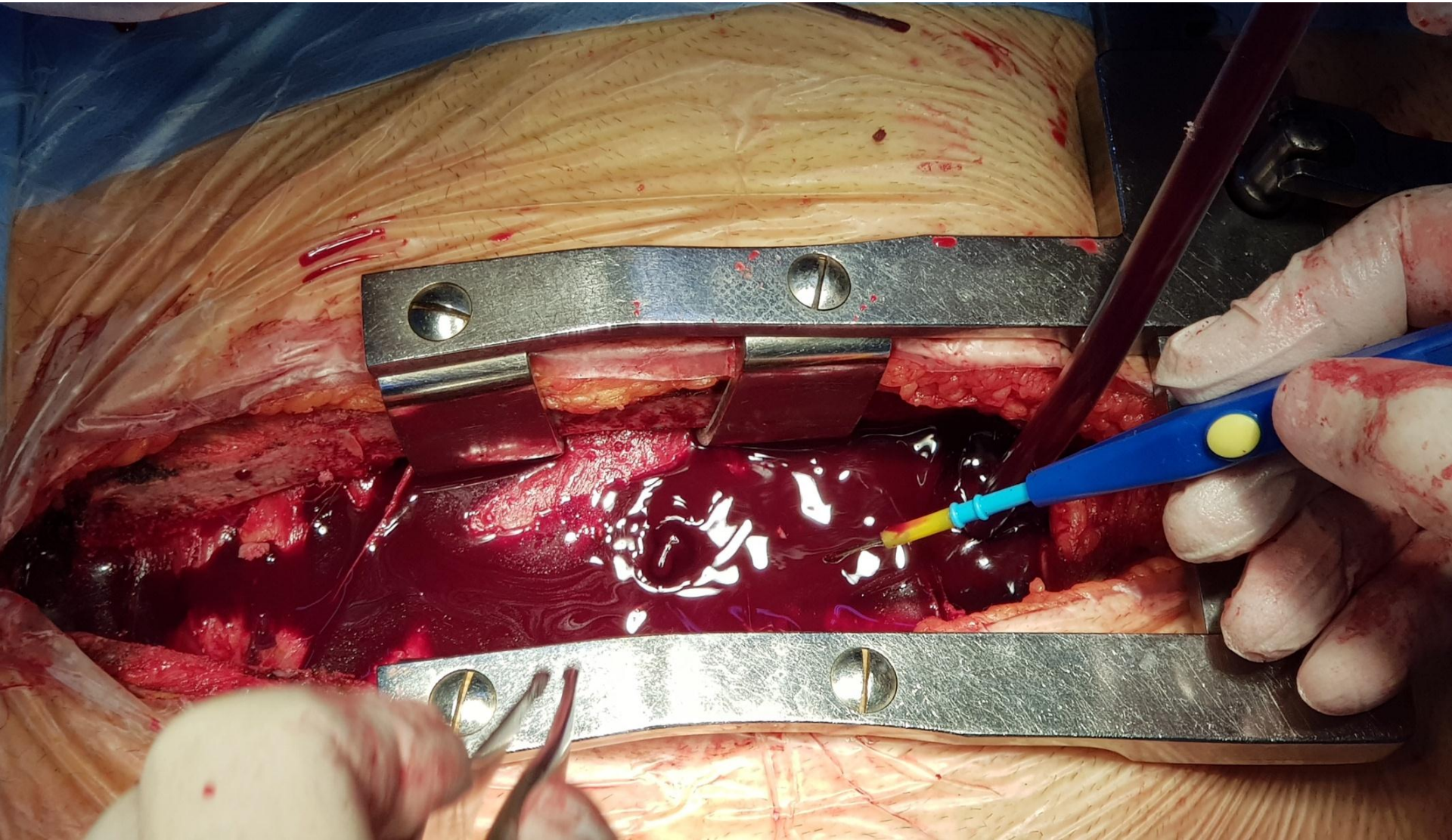

Right Atrial Cannulation

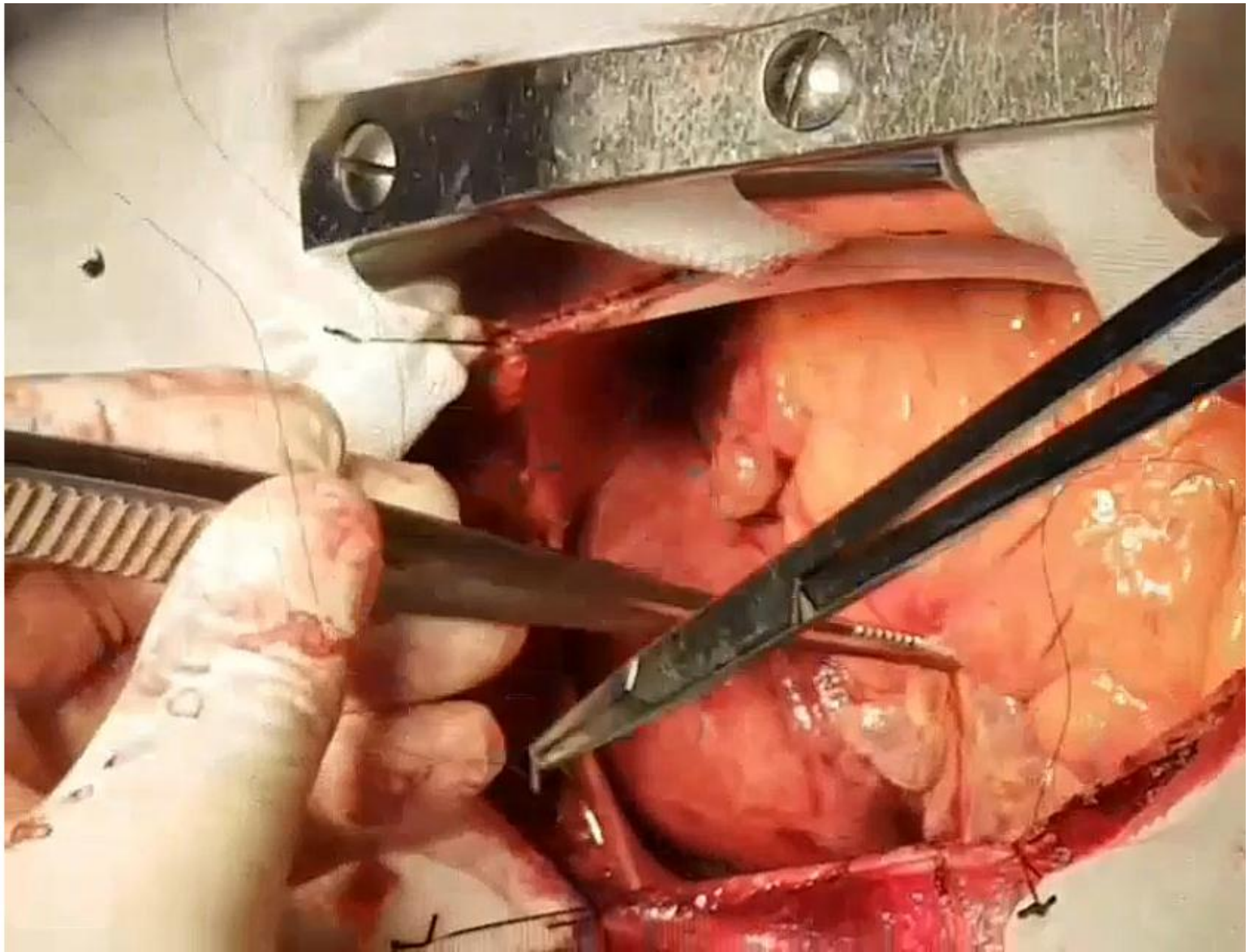

Intramural Hematoma

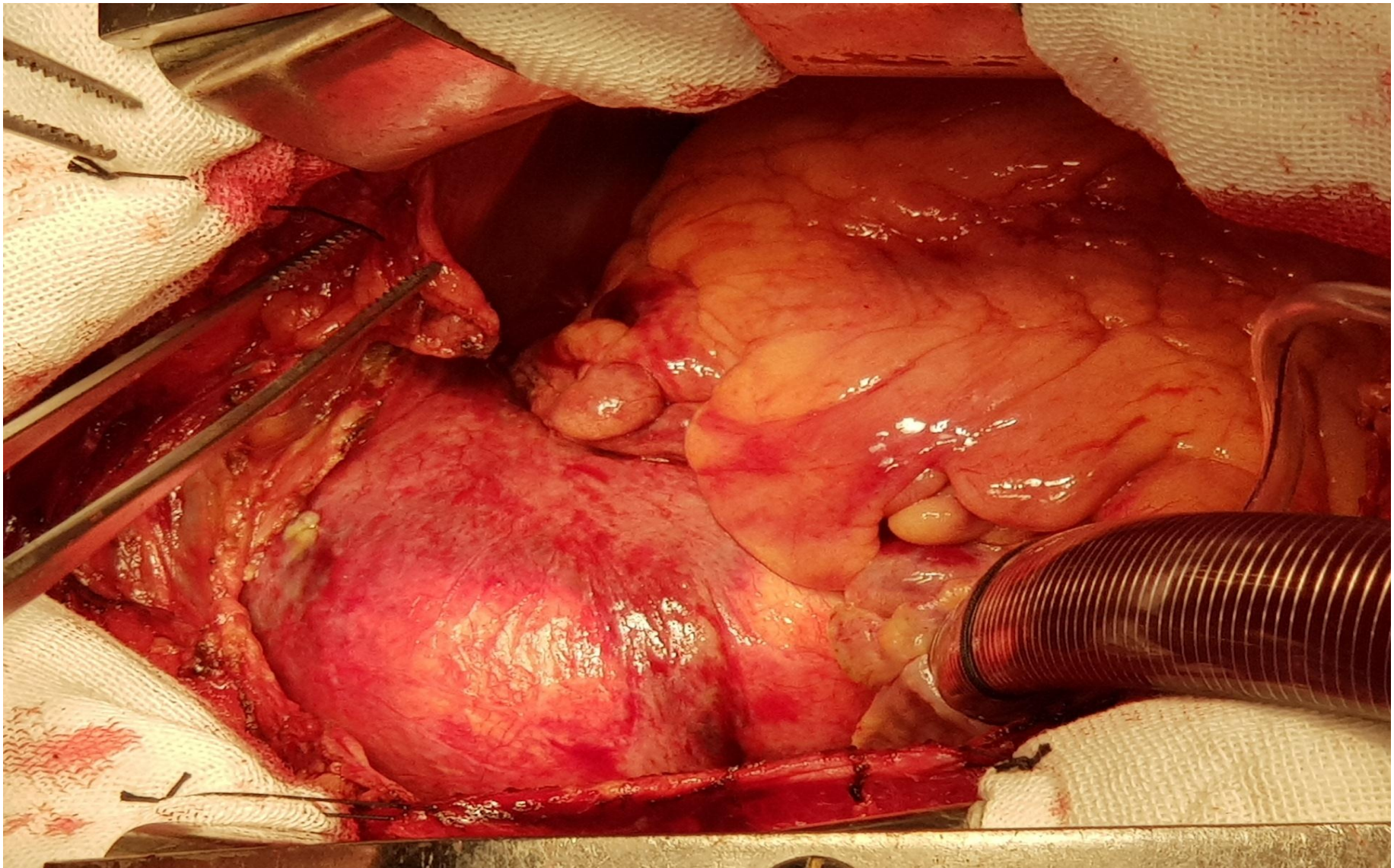

Innominate Vein Exclusion

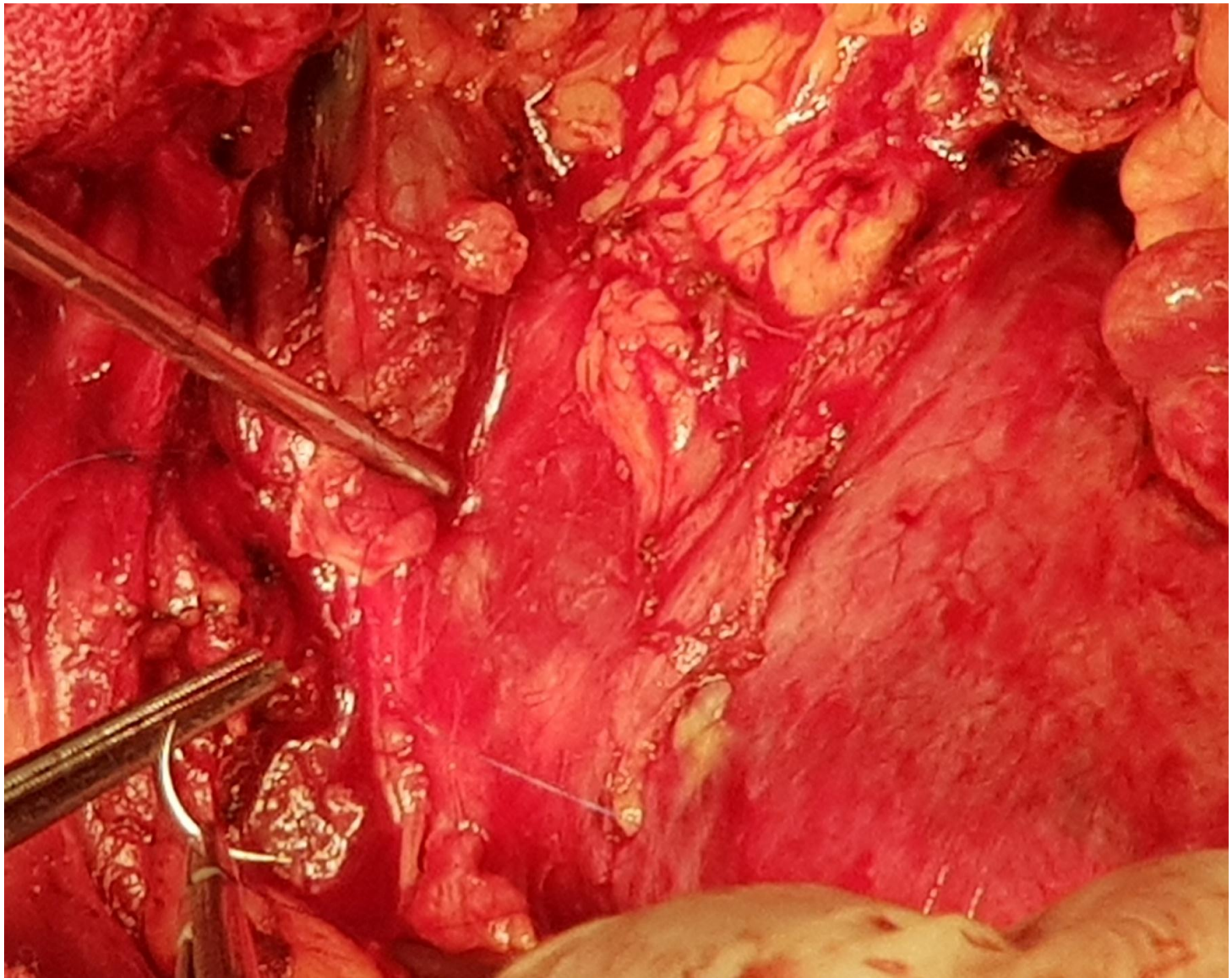

Distal Ascending Aortic Clamp

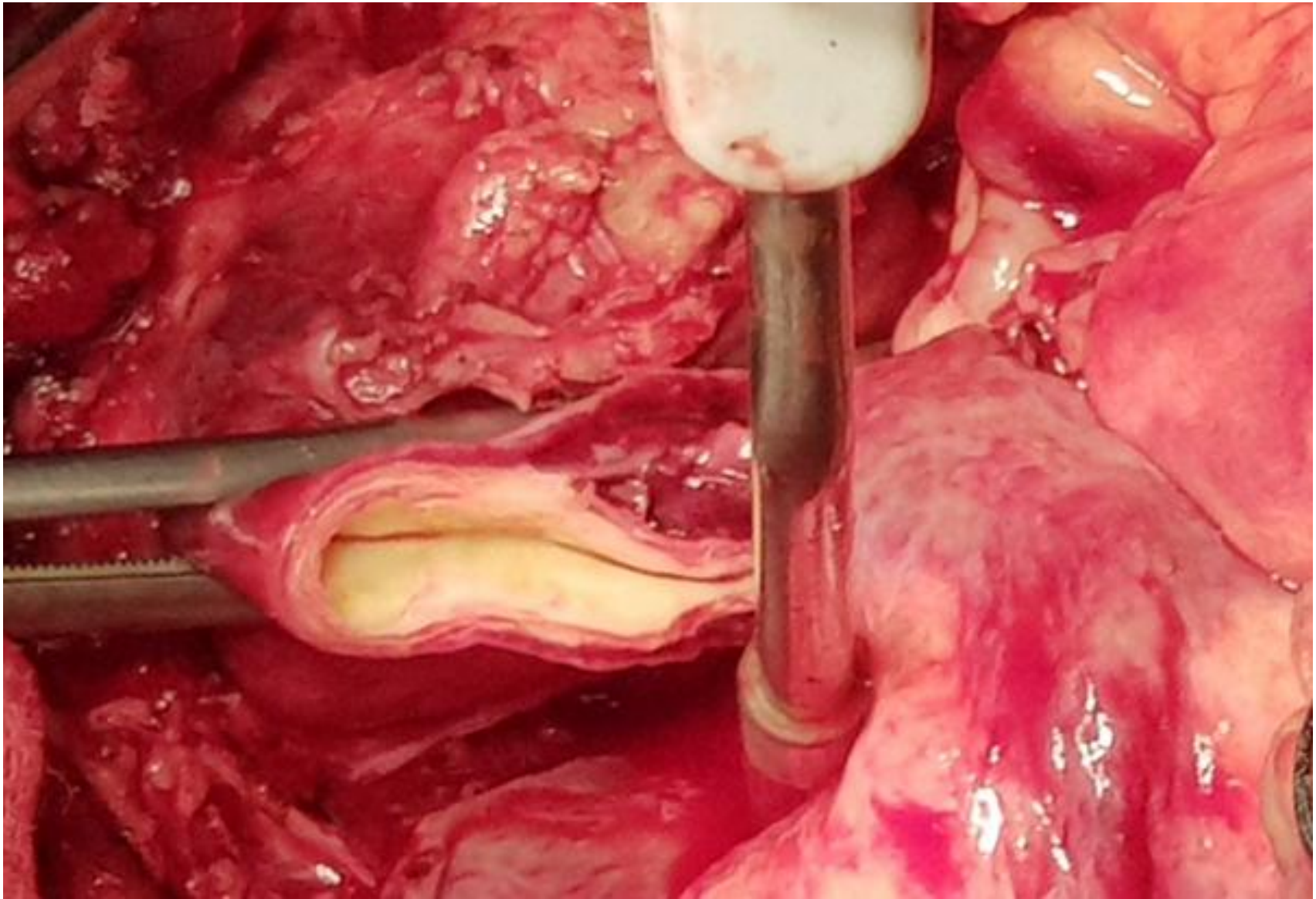

Deep Hypothermia : 24° **Femoral** Circulatory Arrest: **30 min**

Removing Clamp : Open Lumen

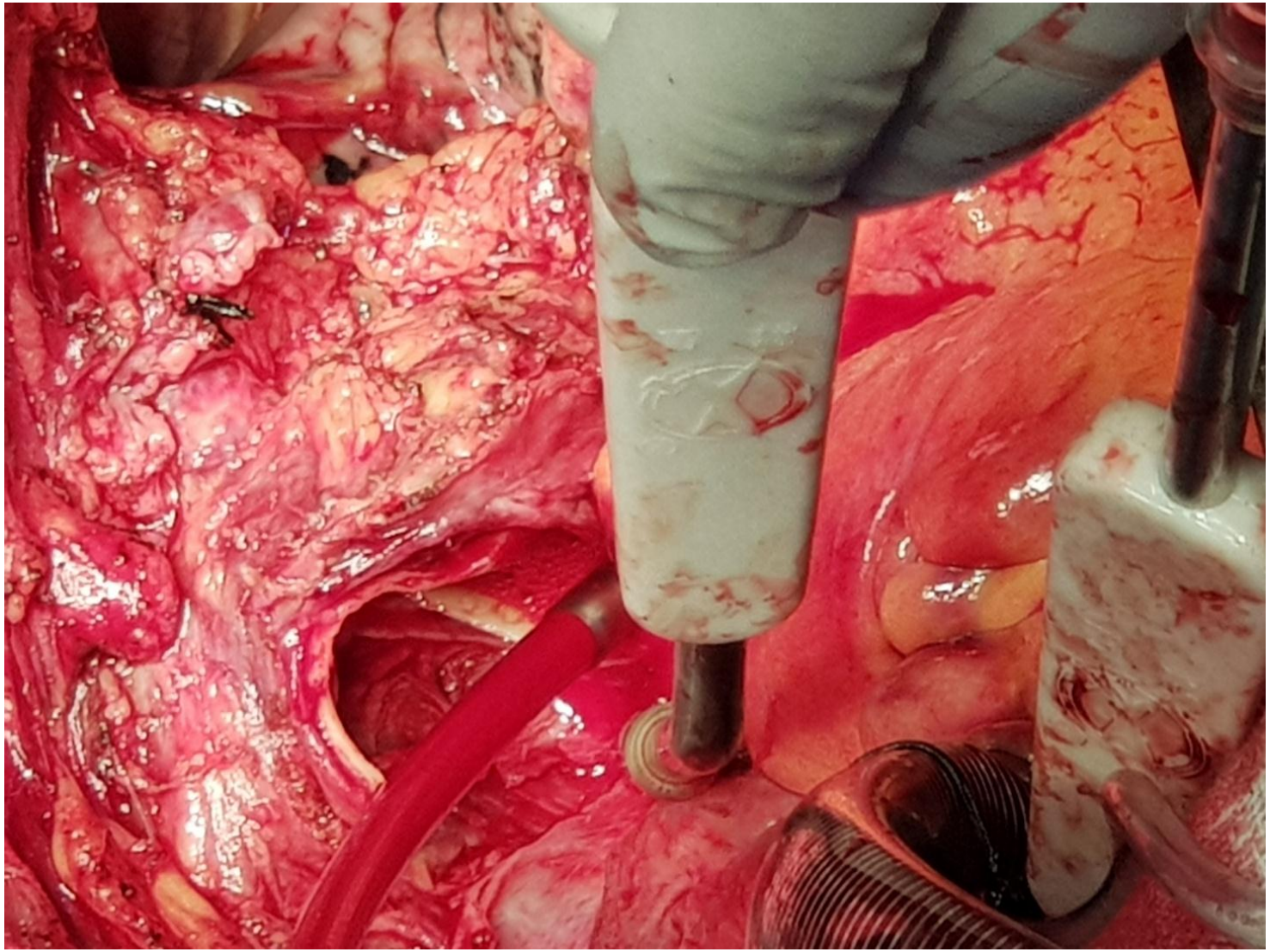

Distal Anastomosis Near the Origin of **Brachiocephalic** Trunk

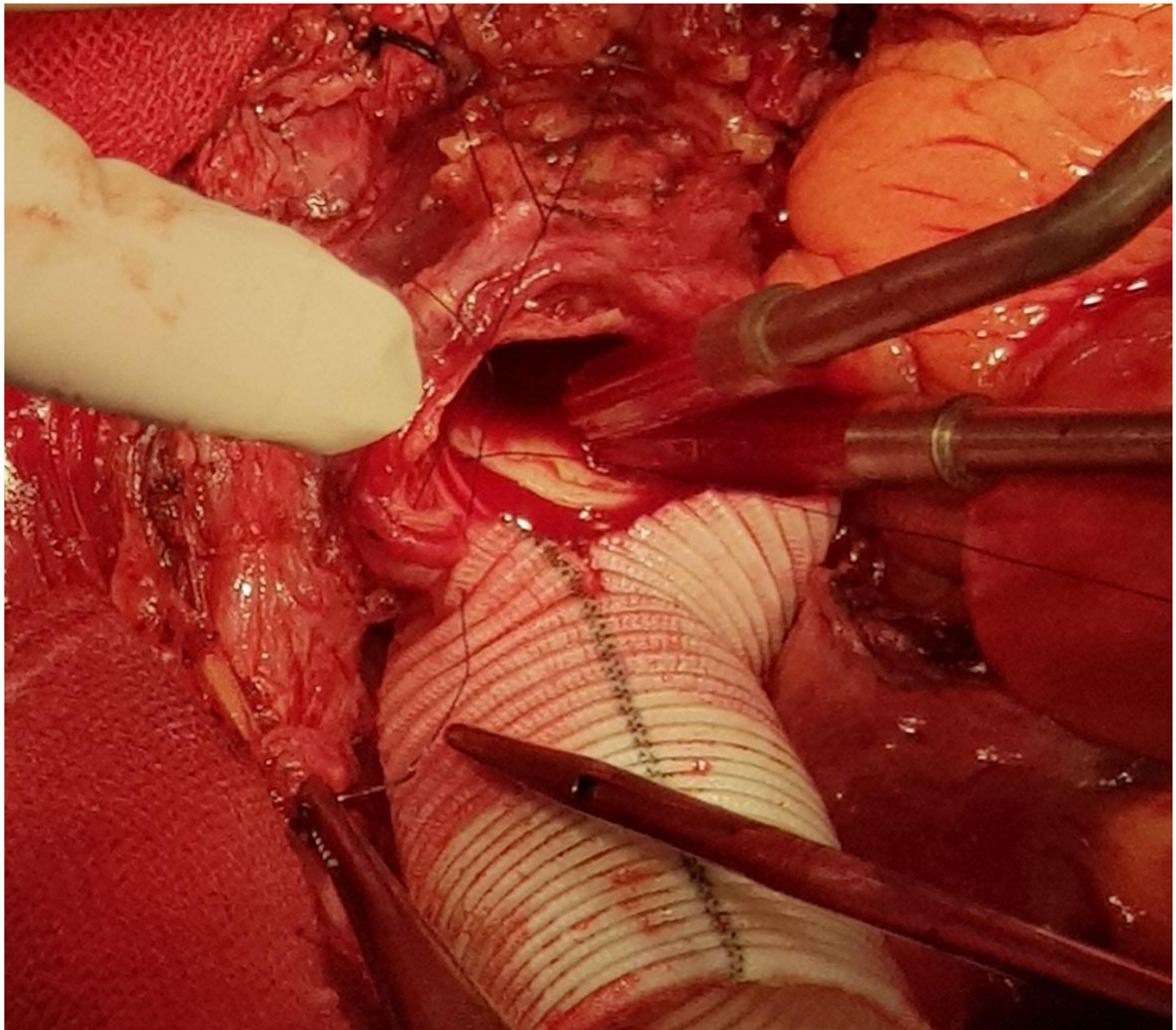

Rewarming
Restoration of Femoral circulation
ReClamping

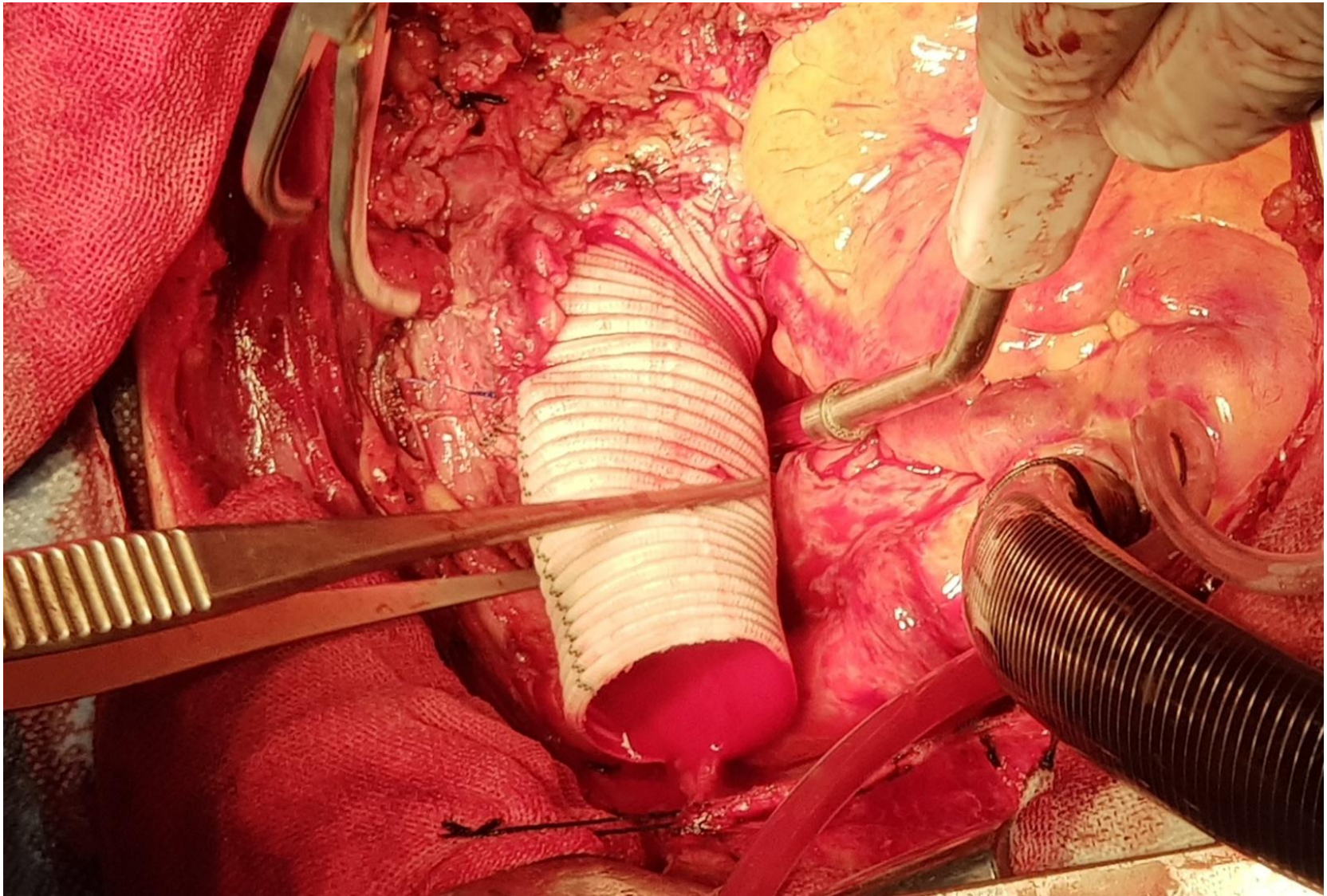

Proximal Anastomosis: **3-4 cm above STJ**

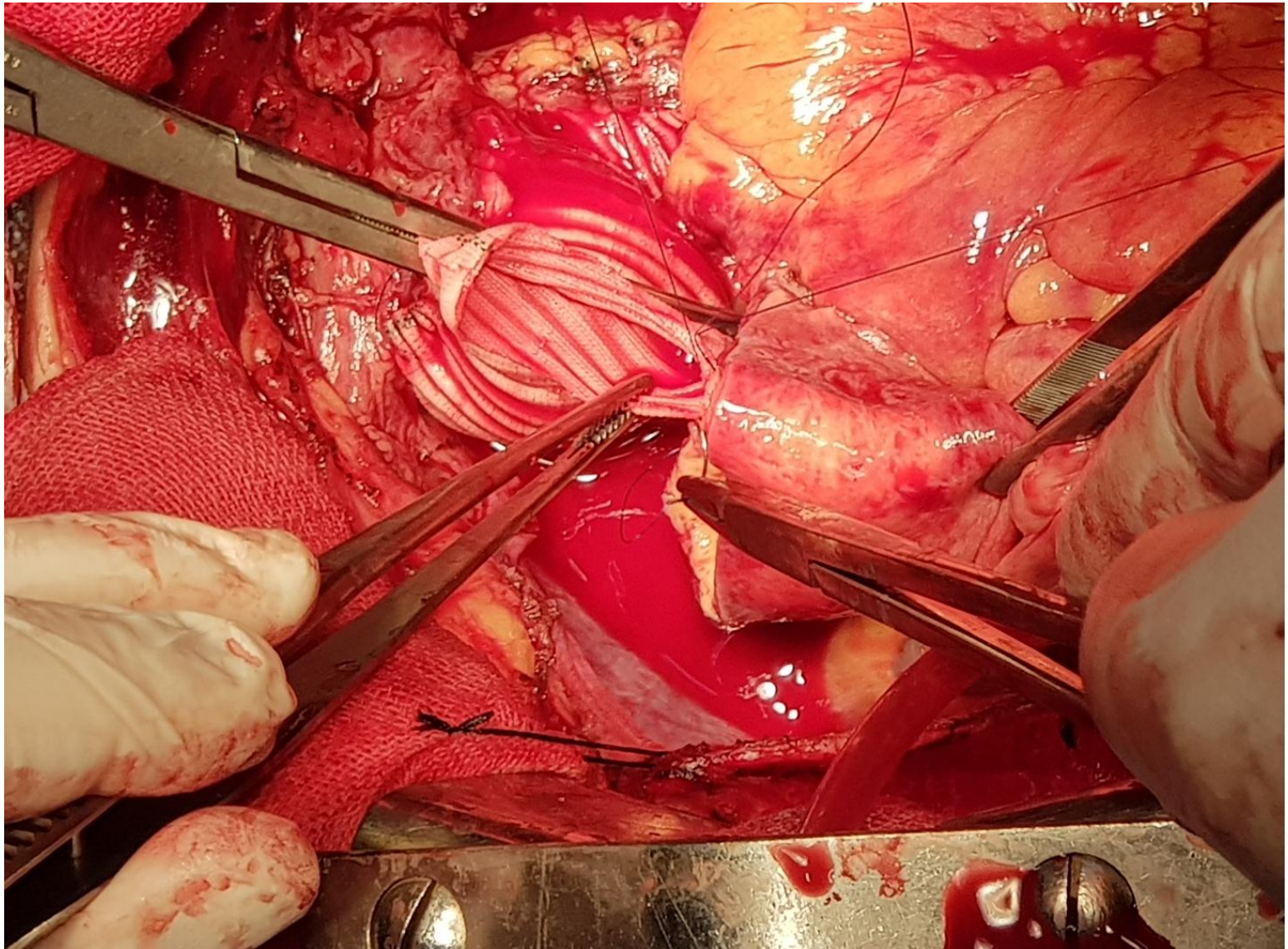

Removing Cross Clamp
Deairing

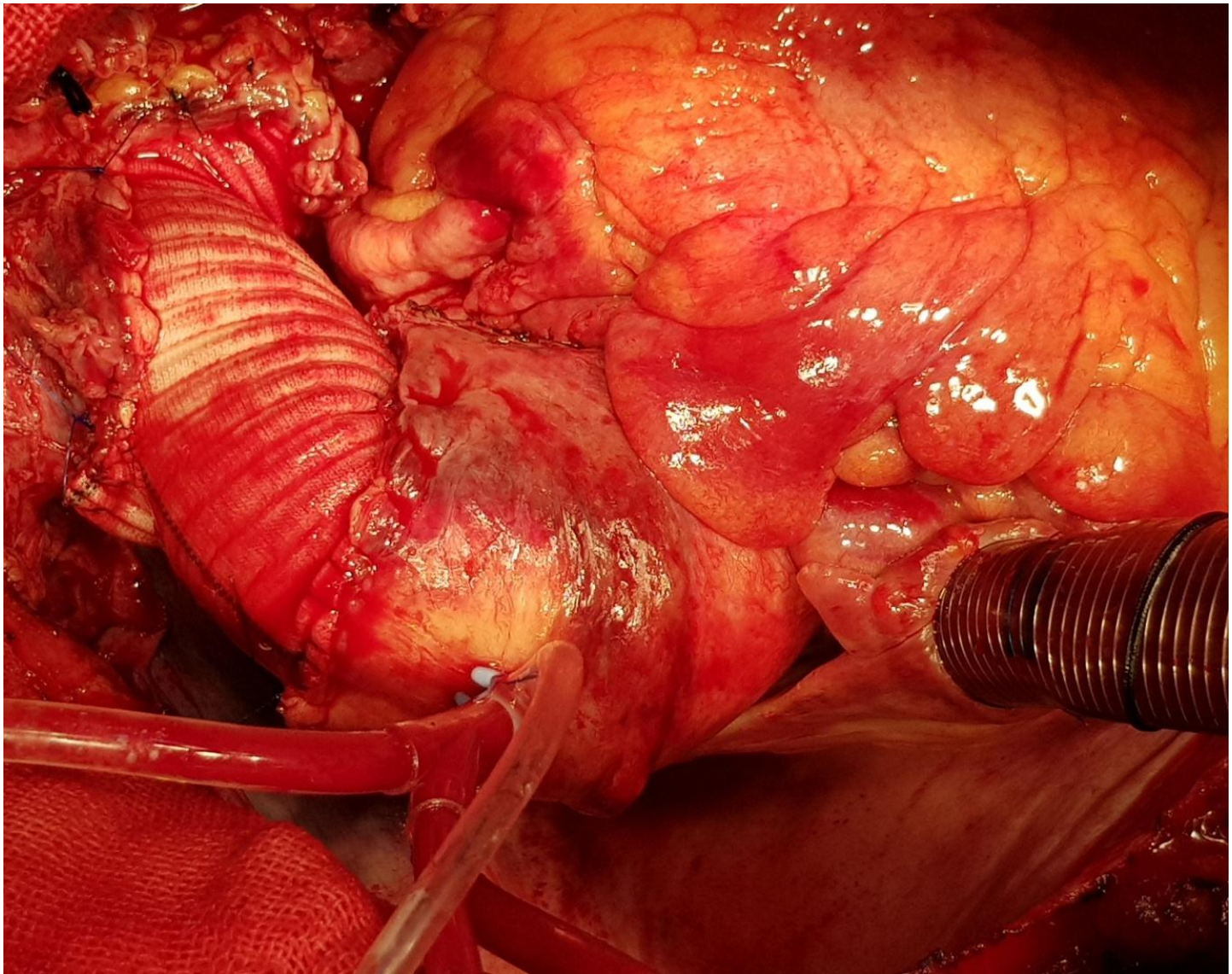

Gauze **Pack** removed **36 hr** later

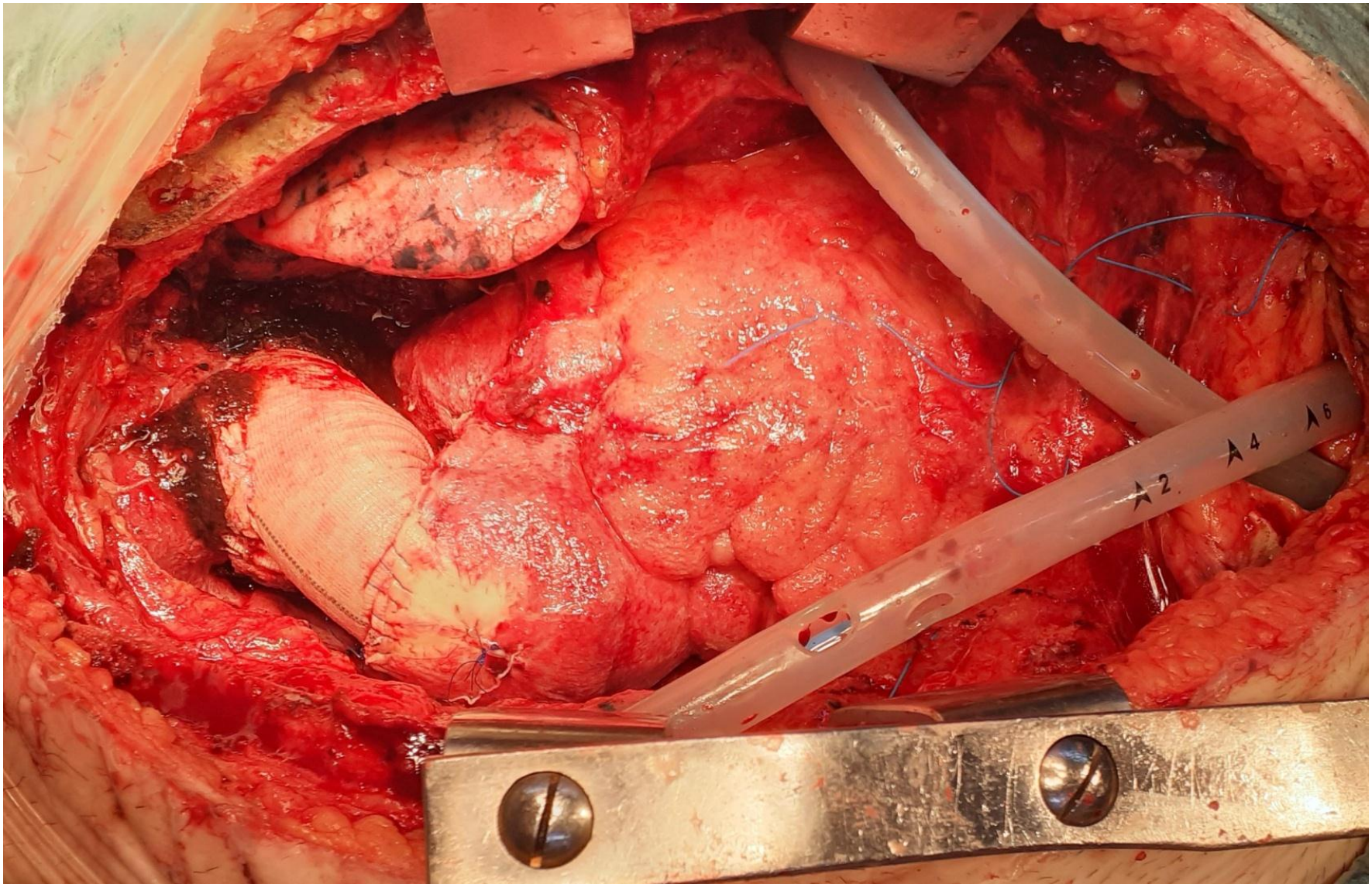

Thank you